

Abstract 304

DTI-TMS assessment of corticospinal tract and corpus callosum integrity in ischemic stroke patients with relation to their motor outcome at the chronic stage

Session Type: Scientific Session

Topic: Preclinical Studies and Basic Science / Diffusion imaging

Authors: S. Kulikova¹, M. Piradov², R. Konovalov³, A. Limonova⁴, L. Dobrynina⁵, M. Nazarova⁶;

¹Perm,RU,National Research University Higher School of Economics,Laboratory of Interdisciplinary Empirical Studies, ²Moscow,RU,Research Center of Neurology,Neurology, ³Moscow,RU,Research Center of Neurology,Neuroradiology, ⁴Moscow,RU,Moscow State University, Faculty of Fundamental Medicine, ⁵Moscow,RU,Research center of neurology,3rd clinical department, ⁶Moscow,RU,National Research University Higher School of Economics, Centre for Cognition and Decision Making

Purpose / Introduction

Adequate assessment of individual functional motor potentials is important for developing appropriate rehabilitation strategies in ischemic stroke [1]. Microstructural changes in corticospinal tract (CST) and corpus callosum (CC) were repeatedly correlated to post-stroke outcome [2,3]. However, relationship between them and functional recovery remains unclear. Here we investigated relationship between integrity of CST and CC assessed with diffusion tensor imaging (DTI) and brain functional state assessed with navigated transcranial magnetic stimulation (nTMS) in chronic ischemic supratentorial stroke.

Subjects and Methods

35 patients (45±9y) from different motor outcome groups: I – favorable (N=8); II – moderate (N=6); III - unfavorable (N=21) were compared to 30 age-matched healthy volunteers. CST and CC integrity was characterized using fractional anisotropy (FA) from DTI (1.5T Siemens, 20 directions, b-value=1000). Voxels with reduced FA were correlated with motor outcome and nTMS measures (Nexstim): resting motor thresholds (RMT) for *Abductor Pollicis Brevis* (APB) and *Extensor Digitorum Communis* (EDC) and intracortical inhibition (SICI). FA asymmetry was calculated in the internal capsule (FA-IC) and between corresponding points along ipsilesional and contralesional CST. Ipsilesional and contralesional (CORRp) or control (CORRc) FA profiles for CST were also correlated. Data was processed in BrainVISA and SPM8 software.

Results

In patients compared to volunteers FA was decreased over the whole CC and bilaterally in CST, while differences between groups I and III were localized in callosal motor fibers and ipsilesional CST (Fig.1). FA within IC negatively correlated with RMTs in both hemispheres (Fig.1).

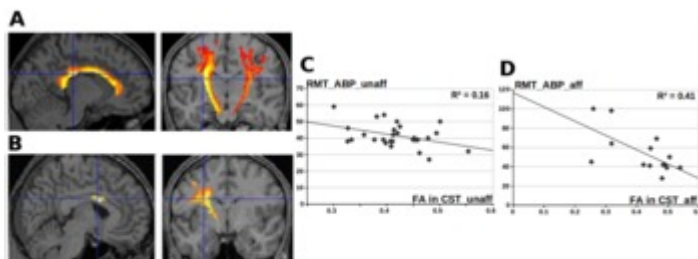


Fig.1 A) Voxels within CC (left) and CST (right) showing decreased FA values in patients compared to control groups (p<0.001, FWE-corrected). B) Voxels within CC (left) and CST (right) showing decreased FA values in group III compared to group I (p<0.02, FWE-corrected). C) Negative correlation between RMT for unaffected APB and FA in unaffected CST (p<0.02). D) Negative correlation between RMT for affected APB and FA in affected CST(p<0.003).

The best predictors of unfavourable outcome were FA-IC asymmetry, average asymmetry for 3 specific points on FA profiles, CORRp, CORRc, FA in selected voxels on CC and CST, and absence of motor evoked potentials (MEP) (Fig.2). Neither DTI nor TMS parameters could discriminate patients between the 3 groups. Surprisingly, this could be done with a 86% success rate using a combination FA-IC+CORRp+CORRc.

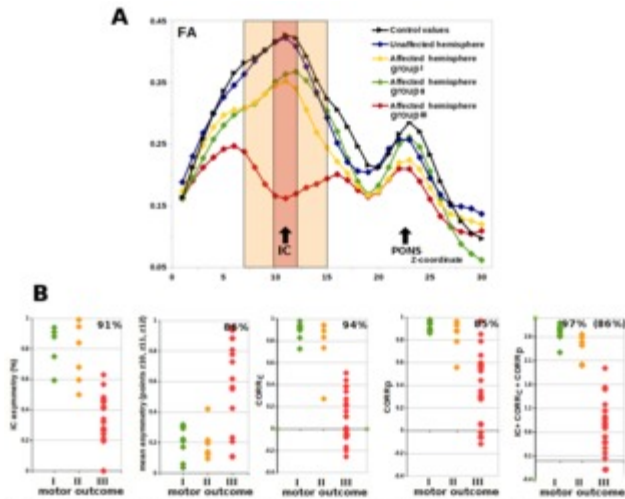


Fig.2 A) FA profiles along CST in control group, in unaffected hemisphere of all patients and in affected hemisphere according to different motor outcome groups. Colored region shows the most discriminative area for motor outcome in patients. B) Distributions of different parameters for the 3 motor outcome groups. Numbers indicate success rate for classification between patients with unfavourable outcome and other patients. For combination FA-IC+CORRp+CORRc 86% is a success rate in 3-group classification.

Discussion / Conclusion

Although low CST and CC integrity and MEPs absence in the affected hemisphere predicted unfavourable outcome, only combination of several parameters could differentiate between the 3 groups suggesting that evaluation of recovery potentials may benefit from multiparametric strategies. Interestingly, unfavourable outcome group demonstrated also lower integrity of the unaffected CST than healthy individuals.

Correlation between FA in IC and RMTs was stronger in the ipsilesional side, while in the contralesional side it was significant but weak [4]. Changes in unaffected CST and CC highlight importance of interhemispheric interactions during stroke recovery, however no correlation between CC integrity and TMS parameters was found.

References

- [1] Auriat et al. (Frontiers in Neurology, 2015)
- [2] Borich et al. (BMC Neuroscience, 2012)
- [3] Lindenberg et al. (HBM, 2012)
- [4] Klöppel et al. (Neuroimage, 2008)

Print